

## Original Article



## Variations in the branches of Abdominal Aorta- A cadaveric study

Iju Shrestha<sup>1</sup>, Nripendra Tiwari<sup>1</sup>, Deepesh Budhathoki<sup>1</sup>, Sushma Khatiwada<sup>2</sup>

<sup>1</sup>Department of Anatomy, Kathmandu Medical College and Teaching Hospital, Duwakot, Bhaktapur.

<sup>2</sup>Department of Anatomy, Chitwan Medical College, Chitwan.

### ABSTRACT

**Introduction:** Variations in abdominal aorta and its branches, which occur due to embryological developmental changes, are frequently observed. Knowledge of these variations and their relation to surrounding structures is important in regards to various intra-abdominal procedures. The study aims to assess the variations present in branching pattern of abdominal aorta.

**Methods:** This cross sectional descriptive study was carried out in the Department of Anatomy, Kathmandu Medical College and Teaching Hospital, Duwakot on all the cadavers received during previous two years. Carefully dissected abdominal aorta was observed for the origin of its branches, and branching pattern and variations found were recorded in prepared table form.

**Results:** In this study, twenty adult cadavers available in the department for study purpose were dissected. Out of twenty, twelve cadavers were of males and eight were of females. Two (10%) of them showed variation in the origins of inferior mesenteric and the gonadal arteries. No variations were observed in relation to other branches of the aorta.

**Conclusion:** The variation of branches of abdominal aorta do occur sporadically thus knowledge of the anatomy may be helpful in diagnostic and surgical procedure. .

**Keywords:** abdominal aorta; cadavers; variations of anatomy

**Citation:** Shrestha, I., Tiwari, N., & Khatiwada, S. Variations in the Branches of Abdominal Aorta- A Cadaveric Study. JKISTMC 2022;4(2)8:40-43

#### Correspondence:

Dr. Iju Shrestha

Lecturer, Department of Anatomy

Kathmandu Medical College and Teaching Hospital,

Duwakot, Bhaktapur.

Email : drijushrestha@gmail.com

ORCID : <https://orcid.org/0000-0002-0719-0738>

**Conflict of Interest:** None

**Source of support:** None

#### Article info:

Received :24 July , 2022

Accepted :27 July, 2022

Published :7 August , 2022

#### Copyright

JKISTMC applies the Creative Commons Attribution-Non Commercial 4.0 International License (CC BY) to all works we publish. Under the CC BY license, authors retain ownership of the copyright for their article, but authors allow anyone to download, reuse, reprint, distribute, and/or copy articles in JKISTMC, so long as the original authors and source are cited.



## INTRODUCTION

The abdominal aorta begins at the median, aortic hiatus of the diaphragm, anterior to twelfth thoracic vertebra's inferior border and the thoracolumbar intervertebral symphysis, descending anterior to the vertebrae to end at the fourth lumbar, a little left to midline, by dividing into two common iliac arteries. The branches of abdominal aorta may be grouped as ventral, dorsal, lateral and terminal.<sup>1</sup> The coeliac trunk is the first anterior branch of abdominal aorta and it arises from the abdominal aorta immediately below the aortic hiatus at the level of T12-L1 vertebrae. Superior mesenteric artery originates 1 cm below the coeliac trunk, at the level of the L1-L2 intervertebral disc. The inferior mesenteric artery arises from the anterior or anterolateral aspect of the abdominal aorta at the level of the L3 and 3-4 cm above aortic bifurcation.

The usual pattern of the coeliac trunk is constituted by the left gastric artery, splenic artery and common hepatic artery and is represented the 86% of cases in a total summary of eight studies.<sup>2</sup> The inferior phrenic arteries usually arise from the aorta, just above the level of the coeliac trunk. The renal arteries arise from the lateral wall of the abdominal aorta at the level of L1 or L2 vertebra, 1.5 cm below the superior mesenteric artery.<sup>3</sup> Usually the right renal artery is situated slightly lower than the left. Gonadal artery (testicular in males and ovarian in females) is the paired branch of abdominal aorta that supplies the male or female reproduction glands and it can exhibit a wide range of origin variations. Usually they arise inferior to the renal artery. The artery may be found duplicated, tripled or quadrupled.<sup>1</sup>

Variations in abdominal aorta and its branches are frequently observed and they occur due to embryological developmental changes. The arteries showing frequent variations include coeliac trunk, renal artery and gonadal artery.

The study was done to know the variation in the branches of abdominal aorta in cadavers because it is important in regard to intra-abdominal surgeries, renal transplantation, renal trauma surgery, radiological imaging and surgical treatment of aortic aneurysms. Ligation or damage of the corresponding branches without knowing the possible variations in laparotomy, nephrectomy, renal transplantation, arterial reconstruction and laparoscopy or in other

surgical applications may cause unpredictable complications, such as segmental or total visceral ischemia and failure.<sup>4</sup>

## METHODS

This was a descriptive cross-sectional study that was carried out in a medical college from May 2021 to July 2021. The study included all the cadavers received during previous two years at Department of Anatomy, Kathmandu Medical College and Teaching Hospital. Ethical clearance from the Institutional Review Committee (Reference No. 0502202104) was obtained.

In the present study, twenty adult cadavers available in the department for the study purpose were taken as sample. Gross dissection was performed and the abdominal aorta was exposed, and documented for the origin of its branches, and branching pattern and variations if present. The observed data were recorded in the prepared table form. The data were then computed and analyzed using Excel 2013 to tabulate the results.

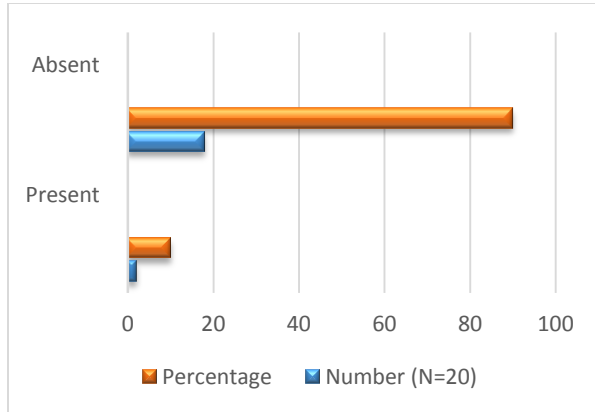
## RESULTS

In this study, twenty adult cadavers available in the department for study purpose were dissected. Out of twenty, twelve cadavers were of males and eight were of females. The branching pattern of the abdominal aorta in eighteen cadavers were normal in their origin, as described in the standard textbooks; and two (10%) of them showed variation in the origins of inferior mesenteric and the gonadal arteries (Figure 1, Table 1).

The origin of the coeliac artery was seen to be within normal levels, with 80% arising at the level of T12 vertebra while rest were at the level intervertebral disc between T12 and L1. The Superior mesenteric artery, 63.15% were seen to arise at the level of intervertebral disc between L1 and L2 and the rest at the level of L2. In one of the cadavers, it was observed to be at the level of lower border of L2 where the inferior mesenteric artery also arose. The inferior mesenteric artery arose at the level of L3 vertebra. In one cadaver, the inferior mesenteric artery originated from the superior mesenteric artery. The branches of the superior mesenteric were in normal pattern except for the inferior mesenteric given off as second branch. The other variation noted was that of

gonadal artery. The gonadal (testicular) artery was seen to arise from the left renal artery. On the right, the pattern was normal. No variations were observed in relation to other branches of the aorta.

**Figure 1. Incidence of variations in branching pattern of abdominal aorta**



**Table 1. Types of variations present in the origin of branches of abdominal aorta**

Variations	Number (%)
Inferior mesenteric artery arising from superior mesenteric artery	1 (5%)
Gonadal artery arising from renal artery	1(5%)

**DISCUSSION**

Variations in abdominal aorta and its one or other branches are frequently observed which have been looked upon with great interest in diagnostic and surgical aspects. The occurrence of these variations has been attributed to embryological developmental changes. Visceral branches of abdominal aorta develop from omphalo-mesenteric arteries [vitelline arteries] and their ventral anastomosis. The regression pattern of these arteries results in variations.<sup>5</sup> In this study,

the variation observed in the branching pattern of abdominal aorta was in two cases.

The origin of the coeliac artery was seen to be within normal levels, with 80% arising at the level of T12 vertebra while rest were at the level intervertebral disc between T12 and L1. The findings are similar to the studies by Arudchelvam J and Butia K et al<sup>5,6</sup> where the origin at T12 level were reported to be 68.3% and 100% respectively. Other studies have reported variations in relation to coeliac trunk which included the inferior phrenic arteries given off from the trunk<sup>7</sup> and the common coeliaco –mesenteric trunk or coeliaco-mesenteric- phrenic trunk<sup>8,9</sup>. However one of the study has also reported absence of coeliac trunk.<sup>10</sup> The superior mesenteric artery in our study showed a regular origin and branching pattern, however, in one case, gave a second branch which was inferior mesenteric artery. Similar origin of IMA has been reported by Yoo SJ et al in a case study.<sup>11</sup> The frequency of IMA arising from SMA has rarely been reported by other researchers, hence Lippert and Pabst<sup>12</sup> mentioned its frequency A to be less than 0.1%. Variations in gonadal artery chiefly testicular artery have also been frequently observed. The gonadal artery (testicular) artery was observed to arise from the left renal artery in this study. In a case study by Naik et al, left gonadal artery has been reported to arise from left accessory renal artery.<sup>13,14</sup> whereas another study has reported the duplication of gonadal artery of which the second arose from the left renal artery.<sup>10</sup> The higher frequency of this variation on the left side can be explained by the fact that during development, the left kidney ascends generally higher than on the right.<sup>15</sup>

Our study agrees with finding of Bhutia K et al where site of bifurcation of aorta was at the level of lower border of the body of the fourth lumbar vertebra.<sup>6</sup> The renal arteries were arising at right angles from the aorta slightly below the superior mesenteric artery<sup>6</sup>. The median sacral artery was seen arising from the back of the aorta almost towards the level of aortic bifurcation. There was no significant variations observed in the branching of other branches of aorta including the lumbar arteries.

**CONCLUSION**

Different forms of variations of branching pattern of the abdominal aorta can be present. Knowledge of such variations can play a

significant role in diagnostic and surgical procedures.

## REFERENCES

1. Gray H. Gray's Anatomy-The Anatomical Basis of Clinical Practice. 39<sup>th</sup> edition. Spain: Elsevier Churchill Livingstone Elsevier Ltd;2005.
2. Bergman RA,Affifi AK,Miyauchi R.Gonadal arteries.In:Arteries [online], <http://www.anatomyatlases.org/AnatomicVariants/Cardiovascular/ext/Arteries/Gonadal.shtml> . 2006
3. Tsikaras P, Paraskevas G, Atsis K. Descriptive and applied anatomy – The circulatory system. Thessaloniki: University Studio Press;2005.
4. Shivarama CH, Shivarama B, Shetty RK, Avadhani R. Multiple Variations Of Branches Of Abdominal Aorta: A Case Study. Nitte University Journal of Health Science. 2012 June; 2(2):48-50.
5. Arudchelvam J. Study on the variations of the ventral abdominal aortic branches:a computed tomography based study. The Sri Lanka Journal of Surgery. 2021; 39(1):26-9.
6. Bhutia K, Sinha P, Tamang B, Sarda RK. Branching pattern of abdominal aorta - a cadaveric study. Int J Health Sci Res. 2016; 6(9):150-155.
7. Prabhakar DV, Santram SM, Raghunath KP, Hanumant GS. Multiple variations in the branching pattern of abdominal aorta. Int J Anat Var. 2014;7:86–8.
8. Manyama M, Lukanima A, Gesase A. A case of celiacomesenteric trunk in a Tanzanian man. BMC Research Notes. 2013;6:34.
9. Nayak S. Common celiaco – mesenterico - phrenic trunk and renal vascular variations. Saudi Medical Journal. 2006; 27:1894-6.
10. Mane UW, Kulkarni YR. Anatomical study of abdominal aorta and its branches for multiple variations. Int J Anat Res. 2016;4(2):2320-7.
11. Yoo SJ, Ku MJ, Cho SS, Yoon SP. A Case of the Inferior Mesenteric Artery Arising from the Superior Mesenteric Artery in a Korean Woman. J Korean Med Sci. 2011 Oct;26(10):1382-5.
12. Lippert H, Pabst R. In: Arterial variations in man: classification and frequency. Munchen: JF Bergmann Verlag. 1985;52-3.
13. Naik KS, Kumar SV, Mahesh GM, et al. Bilateral variations in the branching pattern of abdominal aorta-A case report. Int J Health Sci Res. 2015;5(8): 627-30.
14. Mamatha H, D'Souza AS, Vinodhini P, Ray B, Suhani, Pallav. A Cadaveric Study about the Anomalous Origin of Testicular Arteries Arising from the Accessory Renal Arteries. Indian J Surg. 2015 Mar-Apr; 77(2):111–6.
15. Notkovich H. Variation of testicular and ovarian arteries in relation to the renal pedicle. Surg Gynecol Obstet. 1956;103:487–95.